

Brookville Road Animal Hospital

8049 Brookville Road, Indianapolis, IN 46239

phone: (317) 353-6143

Home Care Instructions

- A bandage wrap has been placed over the ears, to help with the initial bleeding and mess. This is likely to come off over the next 24 hour; if not, please remove the wrap in 2-3 days. Remove slowly and gently. If cutting is required to remove, please cut underneath the opposite ear to avoid cutting the affected ear which is under the bandage, on top of the head.
- Expect small amounts of blood and drainage for the next 2-3 days, especially when the head is shaken. An “e-collar” (cone collar) should be worn when unsupervised until the sutures are removed, to prevent scratching, and to protect your furniture and floors.
- Schedule a recheck examination in 14-20 days. Sutures may be removed at this time.
- Offer normal food tonight.

THE PET HEALTH LIBRARY

By Wendy C. Brooks, DVM, DipABVP

Educational Director, VeterinaryPartner.com

Aural Hematoma



Photo by Dr. Wendy Brooks

A hematoma is swelling created by a broken blood vessel after bleeding has occurred inside a tissue. Hematomas in the earflaps (aural hematomas) occur when head shaking breaks a blood vessel within the earflap. The earflap may partially or completely swell with blood. The swelling may be so large that the opening of the ear canal is blocked off (occluded). The extra weight of the earflap may be uncomfortable and may lead to a permanent change in the carriage of the ears. This condition is more common in dogs but can occur in cats as well. The earflap will feel fluctuant and fluid-filled, like a water balloon.

What do we do to Relieve it?

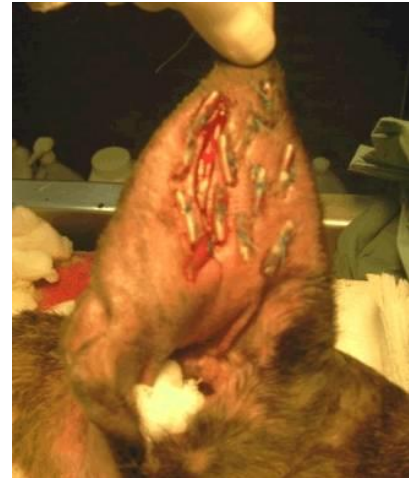There are probably as many ways of correcting ear hematomas as there are veterinarians. The following are some commonly performed procedures:

Aspiration

This simple procedure involves using a syringe to remove the fluid contents from the hematoma. The problem is that a space is left behind when the fluid is removed and this space readily refills with more fluid, leading to temporary results. The benefits of the aspiration method are that it is inexpensive and relatively easy to perform, but the disadvantages are that it may introduce infection and may require multiple attempts. If the clot in the hematoma is already well organized and on its way to scarring, there may not be much fluid left to aspirate and the technique may not work at all. Usually other methods are utilized.

Pie-Crusting Sutures

This method is surgery. Here, an incision is made in the earflap. The hematoma is drained of fluid and blood clots. To prevent the hematoma from refilling with fluid, multiple sutures are placed in the hematoma area vertically or horizontally, either partly through or completely through the earflap, with or without ear cartilage removal. Sometimes bandages are applied post-operatively, sometimes not. Sutures are generally left in place for 3 weeks to allow good scarring to take place so that refilling will not occur. The earflap is essentially quilted to close any space where fluid might refill.



Teat Cannula Placement

Teat cannula is a small device used in the treatment of udder inflammation in cattle. It can be placed in the opening of the teat to allow drainage of milk or infected discharges. Teat cannulas can also be placed in a dog's aural hematoma if the earflap is large enough to accommodate the device. The hematoma is drained of fluids and allowed to heal over the next several weeks. This method is generally successful but does involve the dog tolerating a gadget inserted in its earflap for several weeks.



What if there is a Concurrent Ear Infection?

Usually there is a reason why a dog has been shaking his/her head: an ear infection. This means that the ear infection must be treated along with the hematoma. The ear will need cleaning, microscopic examination of the discharge, and medication. Sometimes ear shaking just happens and there is no underlying infection but be prepared for the expense and trouble of treating an ear infection along with that of the hematoma.

Learn more about [ear infections](#).

What if we Leave it Alone?

If left alone, an ear hematoma will resolve by itself. The fluid will be re-absorbed back into the body and the earflap will no longer bulge. The problem is that a lot of scarring is associated with this process and the ear is often not cosmetically appealing afterwards (it becomes a cauliflower ear). Resolution of a large hematoma can take several months during which it may be uncomfortable for the pet. If the patient is a poor anesthetic risk, it is certainly reasonable to forgo surgery.

Date Published: 1/1/2001

Date Reviewed/Revised: 09/02/2009

THE PET HEALTH LIBRARY

By Wendy C. Brooks, DVM, DipABVP

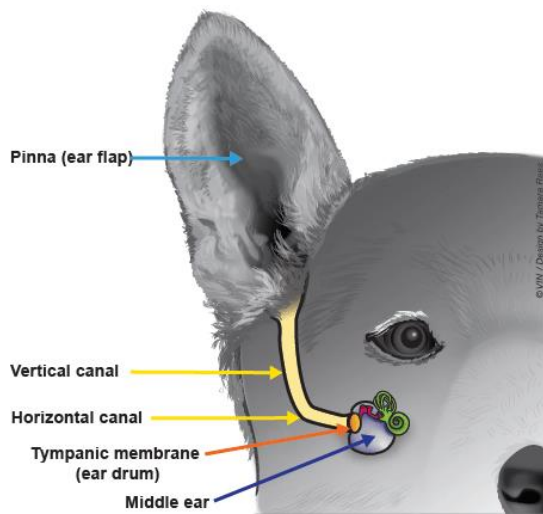
Educational Director, VeterinaryPartner.com

Ear Infections (Otitis Externa)

As demonstrated by the above illustration, a dog's ear canal has a vertical and a horizontal component. This predisposes dogs to ear infections because debris must work its way upward rather than straight out. Accumulation of ear wax, skin oil, and other debris feed the bacteria and fungi that live in the normal ear canal and soon an infection results.

Ear disease usually stems from over-production of wax as occurs in response to irritation. Allergic skin disease affecting the ears is one possible cause, especially in recurring cases; other causes of ear infections include **ear mites**; foreign bodies such as grass awns or foxtails; or hair growth deep in the canal, which is especially common in poodles and schnauzers. The moisture of the wax promotes bacterial growth and infection. Soon wax in the ears is joined by pus.

It isn't long before the pet is seen scratching at his ears, shaking his head or holding one ear slightly dropped. Discharge and odor may be noticeable to people.




Complications of Ear Infection

If the infection reaches the middle ear, affected animals may have a head tilt, a lack of balance, and unusual back-and-forth eye movements called nystagmus. These symptoms are called **vestibular signs** and represent a complication of middle ear infection. Middle ear infections can also cause paralysis of the facial nerve, leading to a slack-jawed appearance on that side of the face.

Aural Hematoma

When a dog with uncomfortable ears shakes and scratches vigorously, a blood vessel in the earflap may rupture. This leads to bleeding into the tissues of the pinna (see above illustration). The usual recommendation is to have the blood clots removed and to bandage and clean the ear under anesthesia. If the hematoma is not so big as to obstruct the ear canal, thus preventing medication of the ear canal, the option to forgo surgery exists; but without surgery, the ear may scar down into an abnormal appearance.



Treating Ear Infections

Step One

Most ear infections are cleared up simply with professional cleaning followed by medication at home. If there is only mild debris in the ear canals, simple disinfection and washing of the ear is adequate; however, in many cases, a full ear flush is needed to even examine the eardrum. For patient comfort, I recommend sedation for this procedure as the ears are sore and the instruments can be damaging if the pet jumps at the wrong time. A sample of ear discharge is commonly examined under the microscope to assist in selecting medications for home use. After a couple of weeks of home treatment, the ear canals are rechecked to be sure the infection is gone. In most cases this completes treatment but for stubborn cases, we must proceed to the next step.

Step Two

Some dogs have chronic ear problems in which the infection is not controlled by general medication or returns when general medication is discontinued. In these cases, the ear discharge should be cultured so that the precise organism can be pinpointed and treated specifically. Regular treatment at home with disinfecting ear washes should become part of the pet's grooming routine.

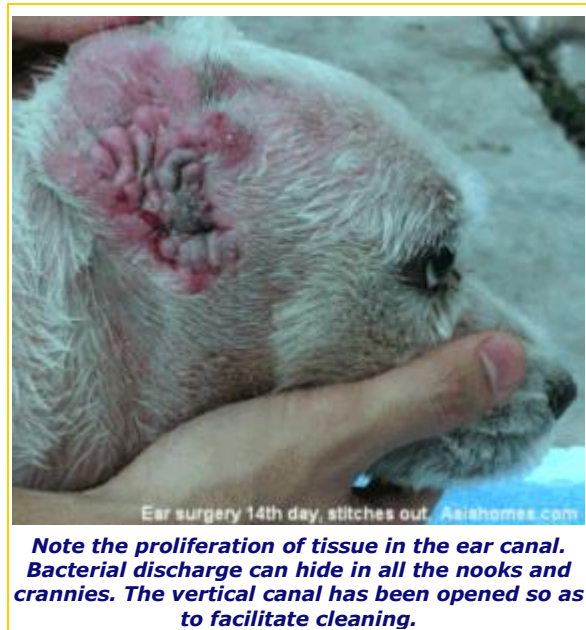Further testing may be in order to determine why the infection continues to recur. Allergy is the most common reason for recurrent ear problems but hormone imbalances can also be underlying causes.

Step Three

Some ear infections simply cannot be controlled with the above steps. These cases go beyond medical management and must proceed to surgery.

Depending on the severity of the problem, the vertical canal may need to be opened surgically. This enables debris to be removed more effectively. This is done to prevent severe scarring after prolonged specific medical therapy has been ineffective. Read more information on the [lateral ear resection](#).

If the canal becomes so scarred that it is practically closed, ablation may be the final option. In this surgical procedure, the entire ear canal is removed and healthy tissue is allowed to grow in. These procedures are last resorts after severe infection has made effective medical treatment impossible. Ablation is a procedure that not all veterinarians are comfortable performing, so discuss with your veterinarian whether a referral to a specialist would be best for you and your pet. Although surgery is expensive, dogs with chronic severe otitis usually require no further ear treatment for the rest of their lives.

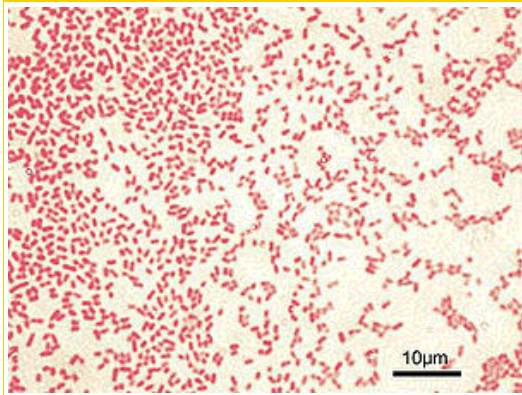


Read more on surgical ear [ablation](#).

Yeast Infection

A fungus is an unusual organism. It typically grows in one of two forms: a fuzzy mycelial (like the mold we see growing on old food) or a microscopic seed-like form called yeast. When people refer to a yeast infection, they are actually talking about an infection with a fungus. A yeast called *Malassezia pachydermatis* lives in most ear canals and on most skin. In normal numbers it causes no problems; however, if the secretions in its environment favor its growth it will proliferate. In large numbers, *Malassezia* produces itching and irritation. Yeast infection with *Malassezia* is the most common type of ear infection in dogs and is frequently accompanied by bacterial infection. As with other types of infection, cleaning and topical medication are important parts of management. Often some kind of cortisone-derivative is needed to cut the inflammation and wax production in the ear canal to create an ear environment less conducive to yeast growth. As with other ear infections, follow up visits are important to prevent chronic on-going issues but if the underlying allergy, hormone-imbalance, ear conformation, etc. is not resolvable, on-going maintenance may be necessary.

***Pseudomonas* Infection**



Pseudomonas aeruginosa

Gram negative rods stain pink with gram staining. Gram negative rods in general tend to be more resistant to antibiotics than gram positive (blue-staining) bacteria. *Pseudomonas* is particularly resistant and able to become still more resistant if treatment is not decisively effective from the beginning. Gram negative ear infections are best cultured promptly so as to identify *Pseudomonas* and take appropriate steps as soon as possible.

Pseudomonas aeruginosa is a specific species of bacteria that is resistant to almost every possible antibiotic. It is common for ear infections to eventually recur and over time, many antibiotics are used. The unfortunate tendency is for most bacteria to be killed off, leaving infection with the resistant and practically

immortal - not to mention especially smelly and pus-causing - *Pseudomonas*.

If one is lucky, a culture of the ear discharge will reveal that the *Pseudomonas* is still sensitive to oral quinolone antibiotics such as **enrofloxacin** or **orbifloxacin**. It should be noted that especially high doses of this type of antibiotic are needed to treat *Pseudomonas* in the ear and that inadequate dosing will just make *Pseudomonas* even more resistant. In other words, *Pseudomonas* must be treated definitively from the moment it is diagnosed; once it becomes resistant to oral therapy, treatment becomes vastly more difficult.

Oral therapy is generally combined with some kind of topical treatment. Fortunately there are several concoctions that should be useful though some must be prepared by your veterinarian personally.

Silvadene/silver sulfadiazine

This product is manufactured as a wound cream and is especially helpful in speeding the healing of damaged external tissues. It also has activity against several bacteria including *Pseudomonas*. The cream can be prepared in water for easier ear administration. This is an especially helpful product if the *Pseudomonas* is resistant to topical antibiotics.

Tris-EDTA

EDTA is a binder of metals that are important to the bacterial cell wall. Tris is used to buffer the EDTA to a pH that is not irritating to the ear and to maximize the anti-bacterial effect. Using Tris-EDTA gives extra power to the topical antibiotics used concurrently.

Injectable Medications

It would be unusual for a *Pseudomonas* species to be resistant to absolutely everything. While there may not be an oral treatment available, sometimes an owner may be taught to give injectable treatments. These are often expensive, however. These same medications can also be mixed up for topical use; many are already available as commercially prepared solutions.

Chronic ear infections, as mentioned, typically have an underlying cause (usually allergy). It is important to address this problem in addition to the infection itself so as to minimize on-going ear inflammation.

Ear infections can be especially frustrating as they have the ability to draw out for months, even years, even with the best of treatment. It is important to have a logical approach, to know what sort of infection is in the ear, to do proper home care regularly, and to **have regular recheck appointments**. If a patient has a history of particularly stubborn ear infections or numerous recurrences, treatment focus shifts to prevention, such as weekly ear disinfection, once the acute infection is eliminated.

Date Published: 1/1/2001

Date Reviewed/Revised: 08/26/2012